

## Editor's Note

August is a very special month for all of us at United Hospital. On 24<sup>th</sup> day of the month in the year 2006, 10 years back, our hospital was inaugurated. We started our OPD from the next day 25<sup>th</sup> August and opened our doors for in-patients on 9<sup>th</sup> September. We remember when the first patient came for registration; when the first patient was admitted in the hospital; when our Cardiac Surgery team performed three cardiac bypass surgeries on their first opening day! Such a memorable journey it was! Even now we have over 90 staffs from the very first day who have completed a decade of patient service in United Hospital.

Today when a patient leaves the hospital healthy & stable, our hearts fill with pride. We stand tall every day, being where we are. We thank all our staff for their long years of dedicated service, for upholding the repute of United Hospital.

We also take this opportunity to congratulate our students of 2<sup>nd</sup> batch Post Basic BSc course of United College of Nursing for their excellent result getting the top 5 positions under the University of Dhaka.

## Completion of 10<sup>th</sup> year of Dedicated Patient Service



Patient-centered care remained the focus of the high quality health care, provided by United Hospital in its first decade. On 24<sup>th</sup> August 2016 the hospital completed its 10<sup>th</sup> year of patient service. During this decade, we've focused on providing superior levels of service, clinical expertise, and customized care plans to fit each patient's lifestyle and individual needs. The day was observed solemnly with raising of the hospital flag at dawn followed by Quran Khani and special prayers. A free health checkup booth at the hospital lobby was inaugurated in the morning by Managing Director, Mr Faridur Rahman Khan and Consultants of the hospital. Special complementary lunch

for all hospital staff including doctors, nurses and all other support staff brought joy to the celebration. Admitted patients were also served with special breakfast dessert with a colourful card wishing them well. The day ended with an evening get together followed by colourful cultural event & dinner; which was attended by Shareholders, Company Board Members & Directors, Consultants, Senior Doctors, Senior Nurses, other senior and mid level staff along with their families. As we step in the second decade, we promise to go further in our commitment to serve the community with better clinical excellence & greater compassion in health care.

## Outstanding Achievement of Students of United College of Nursing



Mr Faridur Rahman Khan, Chairman of United College of Nursing rewarding Ms Sabrina Sultana who obtained 1<sup>st</sup> Position in Post Basic BSc examination (2<sup>nd</sup> Batch)

This year, a total of 229 students from seven government and private nursing colleges appeared for examination under Dhaka University. With 88.20% pass rate, 202 students successfully passed the examination. From United College of Nursing, 30 students appeared in the final examination and passed with a success rate of 97% of which five students got the top five positions in merit list.

Nursing students in merit list are

- 1<sup>st</sup> Position (Sabrina Sultana)
- 2<sup>nd</sup> Position (Rashida Begum)
- 3<sup>rd</sup> position (jointly) Tagar Sarkar & Shahanaj Parvin
- 5<sup>th</sup> position (Mukta Rani Sarker)

The result of the BSc Post Basic nursing course was published recently by Dhaka University. Our students of United College of Nursing achieved a remarkable feat of getting the first 5 positions in the merit list amongst all the nursing colleges under Dhaka University. This is the 2<sup>nd</sup> batch of Post Basic BSc course Session (2013-2014) of UCN.

The Chairman of United College of Nursing, Mr Faridur Rahman Khan awarded these meritorious students in a ceremony and expressed his hope that they will demonstrate their dedication and commitment with similar excellence in their practical work-field. Prof Momtaj Khanam, Principal, United College of Nursing and CEO of United Hospital Mr Najmul Hasan along with other Senior Faculty Members were present in the prize giving ceremony. Congratulations to all UCN students who passed the examination.





## German Oncology Delegates visit United Hospital Cancer Care Centre



A six-member delegate team from Caritas Klinikum University and University of Cologne, Germany visited United Hospital Cancer Care Centre on 26 September 2016. They had an elaborate meeting with Managing Director of United Hospital Limited, Mr Faridur Rahman Khan where they expressed their interest to have a continued collaboration with United Hospital for transfer of knowledge & technology. Mr Faridur Rahman Khan gave them a picture of country's available cancer treatment facilities and contributory role of United Hospital for the skill development of country's medical physicists and oncologists. United Hospital CEO Mr Najmul Hasan was also present in the briefing session. The

team was led by Prof Dr Golam Abu Zakaria Chairman & Chief Medical Physicist of University of Cologne, Germany. Dr Martina Treiber, Head of Radiation Oncology of Caritas Klinikum University of Germany & Medical Physicist Ms Renate Walter were also present among the delegates. Afterwards they had a tour of the cancer care centre and highly praised visiting the only TrueBeam & Medical Cyclotron of the country and the international standard PET CT based planning and simulation, SPECT CT and Brachy-Therapy facility of the hospital. Consultants of United Hospital Radiation Oncology and Medical Physicist team accompanied and showed them around the facility.

## World Heart Day 29 September 2016 commemoration



On 29<sup>th</sup> September Thursday, World Heart Day 2016 was commemorated in a befitting manner. Complimentary health check-up booth was inaugurated in the morning by Mr. Najmul Hasan, Chief Executive Officer of United Hospital along with the consultants of the hospital. Special Heart Screening Check-up package was launched with attractive discount and awareness banners were hung in nearby Gulshan Lake Park, Baridhara Park etc. A lively & interactive patient get-together with patients who took treatment from United Hospital Cardiac Centre was organized in the afternoon. Dr Jahangir Kabir, Chief Cardiac Surgeon gave brief overview on the evolution of heart disease

management in Bangladesh from inception till date; Dr N A M Momenuzzaman Chief Cardiology Consultant highlighted the role of United Hospital in acute chest pain doing 24/7 Primary PCI; Dr Fatema Begum, Consultant Cardiologist put light on increasing heart risk among female population stressing on the need to be aware of it; Dr Kaiser Nasrullah Khan, Consultant Cardiologist emphasized on the international standard cardiac care that United Hospital provides underscoring there is no need to go abroad for these treatment any more. Renowned social & media personalities attended the program, sharing their experience. Amongst them Nayak Raaj Razzak, ex Chief Election Commissioner Mr ATM Shamsul Huda and CEO of ATN Bangla Mr Sarker Firoz Uddin spoke on the occasion. Which was covered hugely by print and TV Media.



## Role of Total Parenteral Nutrition (TPN) in Patient Management

**Chowdhury Tasneem Hasin**

TPN is a miracle, in that it keeps people alive where they cannot eat to sustain themselves. TPN stands for Total Parenteral Nutrition. This is an alternate form of providing a complete form of nutrition, containing protein, carbohydrate, fat, added vitamins and minerals to those patients who are unable to get full nutrition from any enteral route. This method bypasses the digestive tract completely and places nutrients directly into the bloodstream. Total parenteral nutrition (TPN) is required at the time of massive gastrointestinal bleedings, short bowel syndrome, paralytic ileus, severe and prolonged diarrhea not responding to any oral or intravenous therapy, intractable vomiting for a continued period, patients with disorders requiring complete bowel rest, critically ill patients on mechanical ventilator for a longer period, severely undernourished patients, patients of severe burns or head trauma and for those who are being prepared for any surgical cause, radiation therapy or chemotherapy; as an attempt to increase their caloric intake to reverse the weight loss and improve

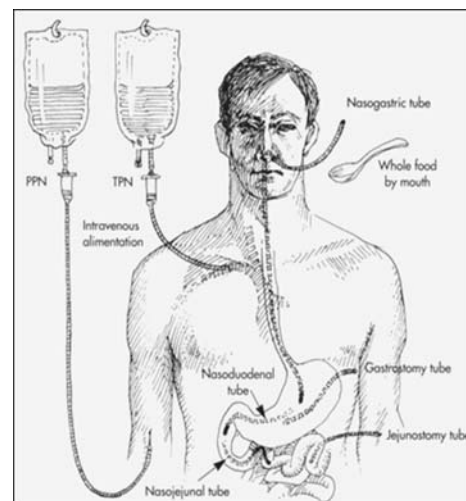
survival. TPN is also suggested for sick or premature newborns before starting other feedings or when they cannot absorb nutrients through the gastrointestinal tract for a long time. TPN therapy should initially be tailored according to the needs of the particular patient.

At the time of monitoring, the TPN advice should be sought from the nutrition team and dietitian. The following should be assessed on a daily basis to provide a well-tailored TPN to the patient.

- Fluid balance
- Serum Cholesterol
- Serum Urea, Electrolytes, Phosphate
- Serum glucose
- Liver function tests adequate to assess for protein synthesis to have an early indication of TPN-related complications.

The patient's total calorie or energy requirement is calculated based on body size and metabolic stress.

TPN costs approximately four times more than the cost of enteral feeding. It



demands critical examination and monitoring.

TPN has proven to be a safe and a life-saving solution for critically ill patients who are unable to take nutrients from any other route. However, we need more randomized controlled trials concerning efficacy of TPN and its cost analyses.

## Importance of Echocardiographic Evaluation of Right ventricular function

**Dr Samsun Nahar**

Assessment of right ventricular (RV) function is an important component of the comprehensive evaluation of cardiac function. RV function may be normal when left ventricular (LV) function is depressed, and conversely, RV dysfunction may occur in presence of normal LV function. RV function is affected by and contributes to a number of disease processes, including pulmonary hypertension caused by a variety of lung or pulmonary vascular diseases. Other diseases affect the right ventricular function in different ways, including global, left ventricular or right ventricular specific cardiomyopathy; right ventricular ischaemia or infarction; pulmonary or tricuspid valvular heart disease; and left to right shunts. RV function has proven to be of importance for patient risk stratification in heart failure and is associated with sudden death and exercise limitation.

The right heart may be challenging for any imaging modality because of its position and its thin walls. In echocar-

diography, the most widely used technique, imaging the right ventricle is often crucial for assessing severity of some left heart conditions and for detecting pathologies that affect primarily the right heart. Because of its shape and position behind the sternum, the right heart needs to be imaged from several echocardiographic windows to provide several cross sectional planes. This interrogation should be an integral part of the routine echocardiographic examination. Failure to do so may result in missing a number of abnormalities or underestimating the severity of some pathologies of the right heart.

The majority of proposed methods of echocardiographic assessment of RV function are based on volumetric measurements of the RV. The volume calculation and estimation of ejection fraction (EF) by 2D echocardiography are not ideal for the clinical assessment of RV function because of complex right ventricular shape. But it enables us to

assess the right ventricular function by determining the right ventricular fractional area change (RV FAC) and tricuspid annular plane systolic excursion (TAPSE). RV FAC correlates well with RVEF by MRI. Tissue Doppler velocities are probably the best useful methods in clinical practice. Early impairment in right ventricular diastolic function is evidenced mainly by TDI derived indexes when conventional color Doppler and M-mode echocardiography fails to detect any abnormality. RV systolic velocity derived with TDI is an independent predictor of cardiac death or rehospitalization for heart failure patients and appears to be superior to conventional two-dimensional parameters of right ventricular function. Radionuclide techniques, and recently MRI, have been used for clinical evaluation of right ventricular (RV) function (RVEF) and volumes; but with the introduction of 3D echocardiography, new echocardiographic possibilities for RV evaluation independent of geometrical assumptions have emerged.



## Transcutaneous Bilirubinometry: A Useful Screening Tool for Neonatal Jaundice in Term and Near Babies - A Hospital Based Study

**Dr Nargis Ara Begum, Dr Khorshed Alam, Dr Anamika Shaha, Dr Md Sohel Showmik, Dr Runa Laila, Dr Shahnaz Parvin, Dr Abdur Rahman, Dr Mizanur Rahman**

Hyperbilirubinemia is a common problem in newborn. Most of the cases are benign but severe Hyperbilirubinemia can lead to kernicterus and brain damage which is preventable. The gold standard to assess neonatal Hyperbilirubinemia is serum bilirubin measurement. Unfortunately this procedure is invasive, painful and time consuming. As the consequence of missing severe, hyperbilirubinemia is serious; there is a constant search of find out a safe method to detect jaundice. Transcutaneous bilirubinometry offers objective method of assessing degree of jaundice reducing subjectivity of clinical assessment.

Objective of the study was to evaluate the relationship between transcutaneous bilirubin (TcB) and total serum bilirubin (TSB) and assess whether

transcutaneous bilirubinometry can be used as a valid screening method for detecting jaundice in term and late preterm babies.

A prospective cross-sectional study was performed in well baby nursery of United Hospital Limited, Dhaka from January 2013 to December 2013. Healthy term & late pre term newborn of  $\geq 35$  wk gestation with clinical evidence of jaundice were included in the study. Total serum bilirubin was measured by Dichlorophenyl Diazonin method and transcutaneous bilirubinometer (JM-103) was used to measure transcutaneous bilirubin (TcB) level.

A total of 116 paired samples were analyzed and strong correlation was found between TcB and TSB

(Correlation coefficient 0.8, mean difference 0.83.  $SD \pm 1.96$  and 95% CI 0.6 to 1.06). Post natal age had significant association with TcB (p value 0.01) and TSB (p value 0.031). Requirement of phototherapy in both group were also significant (p value  $<0.001$ ). TcB value of 11 mg/dl was chosen as cut off point corresponding to TSB level 13mg/dl with sensitivity of 90% and specificity of 71%. Levels above this indicate need for blood sampling to take appropriate therapeutic measure.

It was concluded from the study result that Transcutaneous Bilirubinometry is a non-invasive and valid screening tool for assessing jaundice in newborn.

*This article was published in the latest subscription of Bangladesh Journal of Child Health, 2015, Vol 39(3): 116-122*

## A Case of Multiple Myeloma

**Dr Noor-E-Jabeen, Dr Afrin Haque, Dr Zahid Mahmud**

Multiple myeloma is the malignant proliferation of the plasma cells. The median age of diagnosis is 60 to 70 years and male to female ratio is 2:1. Most important clinical features with which most of the patients present, are features of anaemia, bone pain, features of spinal cord compression and renal failure. Diagnosis is confirmed by increased malignant plasma cell in the bone marrow, serum/urinary M protein and skeletal lytic lesions. If two of these criteria are present then diagnosis is confirmed. Management protocol depends on whether patient is symptomatic or not. The treatment includes chemotherapy with or without Haematopoietic Stem Cell Transplant (HSCT), Radiotherapy and/or bisphosphonates. With the advancement of drug therapy, early diagnosis and initiation of treatment, over one third of the patients are now surviving for 5 years or more.

### Case history

A 47 year old hypertensive lady was admitted in United Hospital with the

complaints of fever for 5 days, generalized body ache for 1 month and weakness with occasional exertional dyspnoea for same duration. According to the statement of the patient she was reasonably well 1 month back. Then she developed generalized weakness, fatigue and occasional exertional dyspnoea and on query she gave history of spontaneous nasal bleeding for 3 episodes in the last 1 month. She was also having low grade fever which was not documented at home. Her bowel and bladder habit was normal and there was no history of cough, abdominal pain, joint pain, rashes or oral ulceration.

On examination, she was found to have severe anaemia, tenderness all over the body, more marked on the right lateral chest, no thyromegaly and no lymphadenopathy. BP was 140/90 mm of Hg and pulse was 84/min. All other systems revealed no abnormality.

After admission, her Hb was 5.6 gm/dl and platelet count was 89200/cumm. Her peripheral blood film (PBF)

revealed leuco-erythroblastic blood picture with thrombocytopenia. Serum albumin was 28 gm/l and S. calcium was 2.06 mmol/L. S. protein electrophoresis was done and revealed monoclonal (M band) band in gamma region with hypoalbuminaemia. Urinary Bence-Jones protein was positive,  $\beta$ -2 microglobulin was 3.83 mg/L, S. IgG was 7318 mg/dl. All other biochemical parameters were normal. Bone marrow examination revealed plasma cell disorder probably Multiple Myeloma. So this middle aged lady after thorough examination and investigation was labeled as a case of multiple myeloma. After admission she received 4 units of packed red cell. After confirmation of her diagnosis and proper counseling with patient's attendant regarding her diagnosis and treatment outcome, conservative drug therapy was started with inj. Bortezomib (2mg), cap. Thalidomide (100mg), tablet Dexamethasone (4mg). Then the patient was discharged and she is now getting regular treatment as an out-patient case.

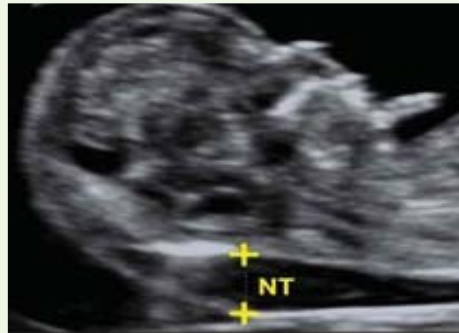## First Trimester Screening in Pregnancy

*Dr Umme Iffat Siddiqua, Prof Dr Shahidullul Islam, Dr. Jan Mohammad*

First trimester screening in pregnancy is a noninvasive prenatal test done between 11 and 14 weeks of pregnancy which offers early information about a baby's risk of certain chromosomal conditions - Down syndrome and trisomy 18. In addition to these abnormalities, a portion of the test (nuchal translucency) can assist in identifying other significant fetal abnormalities, including congenital heart disease, congenital diaphragmatic herniation, omphalocele, skeletal dysplasia and VACTERL association

First trimester screening, also called the first trimester combined test, has two steps:

- Mother's blood test to measure -
  - o Pregnancy- associate plasma protein-A (PAPP-A) and
  - o Human chorionic gonadotropin (free  $\beta$ -hCG).
- An ultrasound exam to measure the size of the clear space in the tissue at the back of the baby's neck (nuchal translucency).



Using maternal age and the results of the blood test and the ultrasound, doctor will provide a risk level (for example 1 in 250 or 1 in 300) from a pre-programmed computer software, which if is moderate or high, patient might choose to follow up with further diagnostic tests such as chorionic villous sampling (CVS) or amniocentesis.

The accuracy rate for this screening to detect the chromosomal abnormalities is approximately 85% with a false positive rate of 5%. This means approximately 85 out of every 100 babies affected by the abnormalities will be

identified in this screening test; approximately 5% of all normal pregnancies will receive a positive result or an abnormal level. A positive test means one has 1 in 100 to 1 in 300 chance of experiencing one of the abnormalities.

The screening test though does not detect neural tube defects.

It is important to realize that first trimester pregnancy screening test is not a diagnostic test and a positive result does not equate to having an abnormality, but rather serves as an indicator to prompt further testing. One will not be given specific quantitative values for the separate parts of the first trimester screen. Instead, one will be told whether the results are "normal or abnormal", and will be given a risk level.

Further diagnostic testing like amniocentesis or chorionic villi biopsy confirm a diagnosis and then provides certain opportunities for expecting parents to make a decision about carrying the child to term, begin planning for a child with special needs and start addressing anticipated lifestyle changes.

## Is There An Optimal Time for Performing Cranioplasties? Results from a Prospective Multinational Study:

*Boon Leong Quah, Hu Liang Low, Mark H. Wilson, Alexios Bimpis, Vincent D.W. Nga, Sein Lwin, Noor Hazlina Zainuddin, Nasser Abd Wahab, Md Al Amin Salek*

The optimal timing of cranioplasty remains uncertain, hence we hypothesized that the risk of infections after primary cranioplasty in adult patients who underwent craniectomy for non-infection related indications are no different when performed early or delayed. We tested this hypothesis in a prospective, multicenter, cohort study.

Data were collected prospectively from 5 neurosurgical centers in the United Kingdom, Malaysia, Singapore, and Bangladesh. Only patients older than 16 years from the time of the non-infection-related Craniectomy were included. The recruitment period was over 17 months, and postoperative follow-up was at least 6 months.

Patients' baseline characteristics, rate of infections, and incidence of hydrocephalus were collected.

Seventy patients were included in this study. There were 25 patients in the early cranioplasty cohort (cranioplasty performed before 12 weeks) and 45 patients in the late cranioplasty cohort (cranioplasty performed after 12 weeks). The follow-up period ranged between 16 and 34 months (mean, 23 months). Baseline characteristics were largely similar but differed only in prophylactic antibiotics received ( $P = 0.28$ ), and primary surgeon performing cranioplasty ( $P = 0.15$ ). There were no infections in the early cranioplasty cohort, whereas 3 infections were

recorded in the late cohort. This did not reach statistical significance ( $P = 0.55$ ).

It was concluded that early cranioplasty in non-infection related Craniectomy is relatively safe. There does not appear to be an added advantage to delaying Cranioplasties more than 12 weeks after the initial Craniectomy in terms of infection reduction. There was no significant difference in infection rates or risk of hydrocephalus between the early and late cohorts.

*This article was published in collaboration with neurosurgery departments of United Kingdom (Queen's Hospital and St. Mary's Hospital), National University Hospital, Singapore, Hospital Pulau Pinang, Malaysia, Trck Puat Hospital and United Hospital Limited Dhaka, Bangladesh*



## 2006 – 2016 . . . . Ten Years of Keeping Promises

On 24<sup>th</sup> August 2016, United Hospital crossed the milestone of 10 years of service to the people of Bangladesh. The most important achievement during this period has been the confidence that our patients have placed on us. Our motto "Exceptional People, Exceptional

day to commemorate occasion.

The hospital hosted a get together and dinner in the evening which was attended by Shareholders, Company Board Members & Directors, Consultants, Senior Doctors, Senior Nurses, other senior and mid level staff together

spoke on the occasion.

Our patients, well wishers & readers would be interested to know that the hospital was conceived by a group of doctors' way back in 80s with the objective of creating an international standard health care facility in Bangladesh.



Care" has been our guiding principle and to which all our staff are committed.

The day was observed solemnly with raising of the hospital flag at dawn which was followed by Quran Khani, and special prayers for the recovery

with their families. Amongst the invitees we had Dr Maj Gen (Retd) A R Khan who was one of the initiator of the hospital in mid 80s. Mr Faridur Rahman the Managing Director of United Hospital presented him with a memorabilia in recognition of his contribution in setting

Late Prof Dr M M Hossain, MRCP, FRCP a cardiologist and a former Director of Red Crescent Hospital in association with some renowned doctor friends including late Maj Gen Dr K M Siraj Jinnat, late Prof Dr Firoza Begum, Maj Gen (Retd) Dr A R Khan envisaged the



and good health of all the patients in general and for the hospital in particular, after Asr prayers. The hospital staff including doctors, nurses and all other support staff had special lunch on the

up the hospital. Mr Faridur Rahman, Managing Director, Major (Dr.) Md. Rezaul Haque (Retd), Director, Mr. Khaleel S. Ahmed, Director and Mr. Najmul Hasan, Chief Executive Officer

concept of the hospital and formed a company in 1985 with 21 shareholders under the name of Continental Hospital. After relentless efforts, with the support and help of the then President Shahabuddin, Prof Hossain was allotted the existing plot by RAJUK, specifically to build a hospital, which was then transferred to the Continental Hospital.

Following award of design and construction contracts, a large number of medical professionals, businessmen and eminent personalities joined hands with the hospital project. By end of



successes, for which each and every one of our staff has contributed and should be congratulated, and we have also learned from our failures and improved and rectified the mistakes. We take pride in our work, our workplace and in our Hospital.

The Chairman and the Board of Directors of United Hospital put special emphasis on education and have approved a number of initiatives with the objective of contributing to healthcare sector of the country. We have an ongoing post graduate course in Cardiology and Cardiac Surgery. The United College of Nursing has been set up to provide BSc course for the nurses.

1995 a seven storied structure covering an area of approximately 350,000 sq ft was built. But unfortunately further work could not be carried out due to a variety of reasons.

No development work took place for a long time and the project remained abandoned. At one stage the Continen-

patients and their attendants step into the hospital they can feel the difference with the greenery outside, the ambient environment inside, the attention each and every patient gets from doctors, nurses and the general staff of the hospital. All our activities are focused on the proper treatment and comfort of our patients.



tal Hospital Board decided to look for a group/ interested investor who would have the drive, enthusiasm and reputation to take up the challenge to implement and finish the project.

In January 2004 United Enterprises & Co Ltd a concern of United Group purchased majority share in the company and thereby became the driving force to implement the dreams of its original dreamers, after almost 20 years. On 24<sup>th</sup> August 2006 our country saw the opening of an entirely different calibre hospital, totally diverse, on a different dimension, THE UNITED HOSPITAL.

The rest is history.

Situated in a quiet corner of Gulshan, away from the hustle and bustle of the city with the Gulshan lake on one side and open space around the building, the environment within the premises is serene and sublime. The moment

We are committed to (i) operating at the highest standards of safe and ethical practice; (ii) selecting the most appropriate services to produce the desired health outcomes; (iii) follow the internationally accepted codes of best practice in all that we do; (iv) care for the physical and mental health of our staff and develop a culture of trust and respect; and (v) provide an environment that promotes learning and personal development.

During the past ten years of service we had our share of successes and failures. We are proud of our

We have an ongoing collaboration with University of Dhaka and the Gono Bishwabidyalay for thesis level studies and to provide training to graduates of Medical Physics department. We also closely work with Bangladesh Atomic Energy Commission and the International Atomic Energy Association on training and educational programmes.

Our goal is to become the finest hospital in the country and to set the standard for healthcare in Bangladesh. We pledge to make our hospital SPECIAL. After all we are *Exceptional People* . . . and we provide *Exceptional Care*.





## A Case Report on Osteochondromas or Osteocartilaginous Exostoses: Common Benign Tumors of the Bones

Dr A H M Rezaul Haque, Dr Masum Billah

The majority of osteochondroma is symptomless and is found incidentally. The tumors take the form of cartilage-capped bony projections or outgrowth on the surface of bones (exostoses). It is characterized as a type of overgrowth that can occur in any bone where cartilage forms bone. These tumors most commonly affect long bones in the leg, pelvis, or scapula (shoulder blade). Development of osteochondroma takes place during skeletal growth between the ages of 13 and 15 and ceases when the growth plate fuses at puberty. Osteochondromas occur in 3% of the general population and represent 35% of all benign tumors and 8% of all bone tumors. The risk of malignant transformation takes place in 1–5% of individuals. Majority of these tumors are solitary non-hereditary lesions and approximately 15% of osteochondromas occur as hereditary multiple osteochondromas (HMOs). Osteochondroma do not result from injury and the exact cause remains unknown. The treatment choice for osteochondroma is surgical removal of

solitary lesion or partial excision of the outgrowth, when symptoms cause motion limitations or nerve and blood vessel impingements.

A 16 year, old male patient was admitted in United Hospital through Out Patient Department as a known case of osteochondroma of right scapula, with swelling on back of right scapula and limitation of movement of right upper limb. MRI of right shoulder joint revealed lesion suggestive of osteochondroma of right scapula. He had no history of any medical co-morbidity



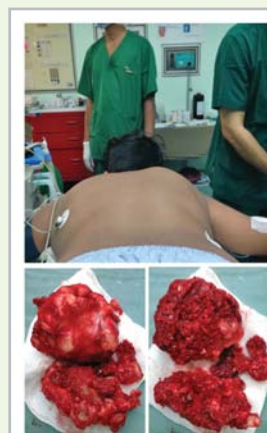MRI & 3D CT Scan

On local examination of right scapular region; there was a swelling of about 3 inches x 2 inches at supero-medial aspect and upper 1/3<sup>rd</sup> of right scapula which was hard, fixed, tender and increasing in size gradually. Redness was present. Range of measurement (ROM) of right shoulder was painful. Right radial pulse was palpable. Patient could move right shoulder, elbow, wrist and all fingers actively. No neurological deficit was found. MRI of right shoulder joint was

suggestive of osteochondroma in right scapular region.

After proper counseling with patient's attendant about the swelling and its treatment outcome, patient underwent total excision of the right scapular mass under General Anesthesia and tissue was sent for histopathology.

There was a lobulated/ cauliflower like bony mass of about size of 5 inches x 4 inches x 3 inches with cartilage cap covered by fibrous perichondrium and continuous with the periosteum of the underlying right scapula, extended from posterior surface of medial angle, part of supraspinatus fossa, half of scapular spine and part of infraspinatus fossa which was excised and sent for histopathological examination. His post-operative period was uneventful.



Surgical removal of the osteochondroma

Patient is in regular follow up, can move the right upper limb actively, distal circulation of right upper limb is normal with no neurological impairment.

## Laser Cordectomy due to bilateral vocal cord palsy

Dr M R Islam

Bilateral vocal cord palsy is an uncommon finding, but can occur after neck surgery or rarely due to a growth in the larynx, pharynx, mediastinum or in thyroid malignancy. It causes severe respiratory distress and stridor and may even cause death of the patient. Hence, early diagnosis and treatment is essential to save the life of the patient.

A 65 year old female patient came to the outpatient department with severe respiratory distress, dysphagia, and progressive difficulty in speech for past 12 months. Her condition became so severe

during last 3 months that she could not lie on the bed at night and had to spend her nights in sitting position or standing upright. She had a history of stroke one year back.

On clinical examination, the patient was found restless, with respiratory difficulty and stridor, she was cachexic and dehydrated. FOL (Fibre optic laryngoscopy) showed bilateral vocal cord palsy (Abductor palsy) with severely compromised airway.

After counseling both the patient and her

attendant regarding treatment plan and outcome, tracheostomy was done to bypass the blocking part of her respiratory passage which allowed her an easier breathing. Six weeks later, Laser Cordectomy was done; on 4<sup>th</sup> post-operative day (POD) clogging of tracheostomy tube was done to make the patient breathe normally. On 7<sup>th</sup> POD tracheostomy tube was removed and wound was closed. On regular follow up, within 2 weeks, her voice improved, her food habit and her airway for normal respiration were found adequate.

## Radicular cyst removal under GA

**Dr Nazrul Islam**

A patient aged 28 years came with the complaint of a large facial swelling with pain. His X-ray revealed a large radiolucent area around an old root canal treated tooth with distal root displacement of both lower canines and incisors. Aspiration of the lesion showed cystic fluid and a clinical diagnosis of a radicular cyst of the jaw was made.

Radicular cysts are usually slow growing and asymptomatic, unless infected or has clinical signs like swelling and teeth displacement. Radiological appearance shows well defined radiolucent area with clear margin and adjacent teeth maybe displaced but don't have root resorption. Clinical aspiration may show cystic fluid which will show cholesterol crystal when dried on a

gauge. Treatment options include marsupialization of the cyst or enucleation of the cyst along with its lining.

In the above mentioned case, surgical inoculation of the cyst was done under GA with bone guttering. Follow up X-ray after 6 month showed good bony healing and no sign of the recurrence at the affected area.

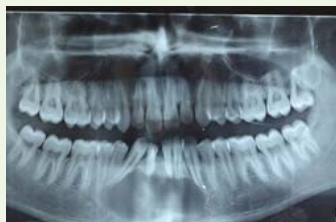

Fig1: X-ray OPG before treatment

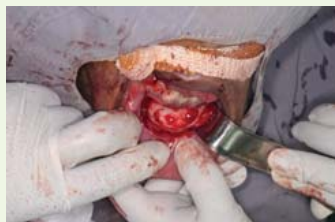

Fig 2: Inoculation of the cyst with its lining



Fig 3: Removed cyst with its lining

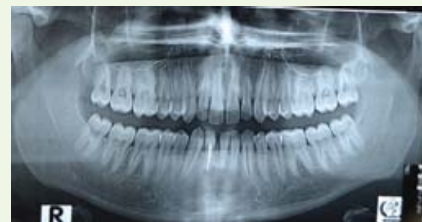

Fig 4: Follow up X-ray OPG after 6 months

## Effect of Spinal Radiation in a young child with advanced radiation technique

**Dr Sharif Ahmed, Dr Rashid Un Nabi, Dr Ashim Kumar Sengupta, Karthick Raj Mani, Anisuzzaman Bhuiyan, Md Faruk Hossain, Anamul Haque**

Spinal gangliogliomas are rare, comprising 1.1% of all spinal cord neoplasms. They are more frequent in children, representing 15% of intramedullary neoplasms in the paediatric age group. The presentation of intramedullary tumours depends on their size and location. The most common presenting symptoms include back/neck pain, radicular pain, weakness, paraesthesia, gait disturbance and bowel and bladder dysfunction. Brown-Sequard syndrome may occur. An uncommon presentation is acute headache due to subarachnoid haemorrhage. In children, progressive scoliosis may be seen. Motor regression and frequent falls may be the presenting features in young children. Symptoms are usually slowly progressive. Due to their non-specific nature, the diagnosis is often delayed. Treatment is usually done by surgery with adjuvant radiation therapy. Radiation is usually delivered to the involved segment in the spinal cord as well as to the uninvolved segment above and below. Review papers suggest that direct decompressive surgery combined with postoperative radiotherapy provide better outcomes than treatment with single modality treatment.

A 4 year 7 months, old boy came to the hospital with complaints of sudden onset of neck bending and leg bending along with pain. There was history of inability to move his right hand for 20 days. There was also history of spine bending backward for 4 months and inability to walk for 3 months. On examination he was afebrile, normotensive, conscious and well alert (GCS 15/15; E4V5M6). On physical examination findings were kyphosis at dorsal region with muscle power of right upper limb 4/5 & left upper limb-5/5 and both lower limb 3/5. Laboratory findings were within normal limits. But MRI of Cervico-thoracic spine was suggestive of syrinx (syringohydromyelia) with astrocytoma; at the level of T3 spine to T7-8 disc and at level of T6-7, T7-8 & T8-9 showed posterior bulging of disc without significant compression on corresponding exiting nerve roots. Surgery was done with Laminectomy at D2- D7 vertebra with myelotomy, decompression of tumour & biopsy. Histopathology report revealed Intramedullary Tumour consistent with ganglioma WHO grade-II. Post operative recovery was good. Patient was planned to treat with adjuvant radiotherapy after stitch removal. Post

operative MRI showed intra-medullary ganglio-glioma at D3-7 level with syringohydromyelia. Radiotherapy was delivered using 6 MV Photon to Spinal region with VMAT (Rapid Arc) to a total Dose of 50 Gy in 25 fractions from 09.11.13 to 11.12.13 with SIB to GTV 50 Gy, CTV 45 & PTV 40Gy. He tolerated the radiation therapy well and there was no complain of severe pain. On follow up, MRI showed minimal interval amelioration of disease process as compared with previous. MRI after 3 months showed fibrotic residual from D1/D2 disc to D7 disc. On regular follow up the patient showed subjective improvement. He was able to walk. His muscle power of both upper and lower limb was 5/5.

This case illustrated that the use of advanced technique in radiation therapy like Volumetric Modulated Arc Therapy (Rapid Arc) can reduce side effect and give facilities to deliver full dose of radiotherapy to the gross tumour volume while restricting the dose to normal tissue and critical organs of body. With the use of advance technique and minimizing the side effects, VMAT can improve the patient's symptoms and long term remission of disease.



## Corporate Agreement Signing

United Hospital Limited signed Corporate Medical Services Agreement with the following companies in this quarter:



- Super Star Group (SSG) on Monday 8 August 2016.
- Eastern Bank Limited on Sunday 14 August 2016.
- JVCA of M/S Guangdong Power Engineering Co. on Wednesday 31 August 2016.
- Kuwait Defence Attache Office on Tuesday 6 September 2016.

## Antenatal Classes for Expectant Mothers



As a part of patient education and consequent value addition to the treatment, "8th Antenatal Class" under the supervision of Obstetrics & Gynaecology Department was organized on Saturday 16 July 2016. Participants were the pregnant mothers with a companion who are availing United Hospital Obstetric prenatal care. Dr Afsari Ahmed, Junior Consultant, Obstetrics & Gynaecology Department, Ms Tasneem Hasin, In-Charge, Dietetics & Nutrition Department, Ms Shimul Chanda, Clinical Physiotherapist and Ms Sajeda, Senior Staff Nurse of United Hospital gave presentation on various topics.

## CSR as Health Awareness Talk



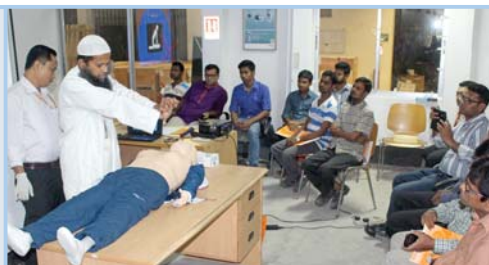To commemorate World Hepatitis Day 2016 and as a part of our CSR activities, United Hospital Limited organized "Health Awareness Session on Liver Diseases and Its Management" for the employees of Seven Rings Cement, Amann Bangladesh Limited, Holcim

Cement (Bangladesh) Limited on Wednesday 03 August, Monday 08 August & Sunday 14 August 2016 respectively. Dr Fowaz Hussain Shuvo, Consultant, Gastroenterology & Hepatology Department of United Hospital conducted all the three sessions. On 25

September, to commemorate World Heart Day an "Awareness Session focusing on World Heart Day" was organized at the corporate office of Grameenphone Limited. Dr Quazi Md Anisujaman, Specialist, Cardiology Department of United Hospital conducted the session. Ms Anika Humaira, Psychosocial Counselor of United Hospital conducted an awareness session on Stress Management at the corporate office of Auko-Tex Group on 21 September 2016.

## CSR as First Aid Training

On Saturday 6 August 2016 a "First Aid Training Programme" for employees of Siemens Bangladesh Limited was organized at their Gazipur Factory Office with a view to create ability for their staff to provide any kind of first aid in real emergency needs. Session was conducted by Dr Md Shafiqul Islam, Senior Emergency Medical Officer &



Coordinator, Emergency Department of United Hospital Limited.





## Training



Ms Farhana Faruque, Librarian, United Hospital attended a workshop on "Health Inter Network Access to Research Initiative (HINARI)" from 16-18 August 2016. The workshop was arranged by Bangladesh Medical Research Council (BMRC) with World Health Organization (WHO).

Nursing Aide Suruchi Drong, Monalesa Rema, Pinki Gomes and Mita Gomes from United Hospital attended "Diabetes Educators Training Program" for two weeks from 20 September 2016 at BIRDEM.



Dhaka Branch Council (DBC), Institute of Cost and Management Accountants of Bangladesh (ICMAB) organized a 6 days training from 16-21 August 2016 on "Income Tax, VAT & Customs" (11 modules) at ICMA Bhaban, Nilkhet, Dhaka. Ms. Nazneen Akter, Accounts Manager & Mr Arif Bhuiyan, Accounts Executive from United Hospital attended the training.

## Seminars

Date	Program Title	Speakers	Discussants
27 July 2016	Endovenous Laser Treatment for Varicose Vein	Mr Saurin Shah Application Specialist of Biolitec, India Dr Jan Mohammad Consultant, Radiology & Imaging	Open Forum Discussion
28 July 2016	Updated Management of Hepatitis	Dr Mohammed Mahbub Alam Consultant, Gastroenterology & Hepatology Dr Fowaz Hussain Shuvo Consultant, Gastroenterology & Hepatology	Open Forum Discussion
4 August 2016	Application of Ultrasound on Liver Elastography	Mr Mahendra Mehra General Manager, Emerging Care Ultrasound, GE Healthcare Ltd, India Dr Sohel Abdullah Sonologist, Radiology & Imaging	Prof Dr Shahidul Islam Consultant, Radiology & Imaging Dr Jan Mohammad Consultant, Radiology & Imaging Dr Mohammed Mahbub Alam Consultant, Gastroenterology & Hepatology Dr Md Iqbal Hussain Consultant, Internal Medicine
1 September 2016	Total Parenteral Nutrition (TPN) & Its Use in Critical Care	Dr Mohd Maniruzzaman Consultant & Chief of ICU Ms Chowdhury Tasneem Hasin In Charge, Dietetics & Nutrition	Dr Mohd Maniruzzaman Consultant & Chief of ICU Dr Nazmul Islam Consultant, Diabetes & Endocrinology Ms Chowdhury Tasneem Hasin In Charge, Dietetics & Nutrition

## National Training Program on Cervical & Genitourinary Cancer

A five days training program from 7 to 11 August 2016 as a part of National Training Program (NTP) on "Cervical Cancer and Genitourinary Malignancy" for Radiation Oncologists and Medical Physicists was organized by Bangladesh Atomic Energy Commission (BAEC) with technical support of International Atomic Energy Agency (IAEA), local support of Oncology Club and United Hospital.

IAEA assigned two trainers, Dr S K Shrivastava, Head of Radiation Oncology, Tata Memorial Hospital, Mumbai and Dr T Ganesh, Head of Medical Physics, Fortis

Hospital, New Delhi with whom Mr Karthick Raj Mani, Consultant Medical Physicist, United Hospital joined as local facilitator for this training program.

Medical Physicists Mr Mohammad Faruk Hossain & Mr Kh Anamul Haque from United Hospital attended the training.

On 10 August 2016, a day long practical session was held at the Department of Radiation Oncology, United Hospital. Live demonstration of Intracavitary

brachytherapy procedure and planning was done for around 35 participants of various Radiotherapy centers of the country.





## New Consultants



**Dr Khan Md Sayeduzzaman**  
MBBS, MCPS (Medicine), MD (Chest Disease)  
**Consultant**  
**Respiratory & Chest Diseases**



**Col (Retd) Prof Dr Mohd Mozibor Rahman**  
MBBS, FCPS (Medicine)  
**Consultant, Neuro Medicine**



**Prof Dr Sk Golam Mostofa**  
MBBS, FCPS  
**Consultant, Radiation Oncology**



**Dr Asif Mujtaba Mahmud**  
MBBS, DTCD, PhD (Japan)  
**Consultant**  
**Respiratory & Chest Diseases**

## Condolence & Prayers

- Customer Relation Officer A N M Bazlar Rashid lost his son Master Tasnim Hasan Rahat on 28 June 2016.
- Specialist Dr Md Rakib Hossain of ENT & Head Neck Surgery lost his mother Mrs. Rehana Akter on 24 July 2016.
- Food & Beverage Department's Kajal Barua lost his baby Arnob on 26 August 2016.
- Radiology & Imaging Department's Junior Consultant Dr. Rumana Sultana lost her father-in-law Mr Alhaz A B Mokbul Ahmed Patowary on 5 October 2016.

## We congratulate the Newly Weds on their marriage

- Housekeeping Department's Attendant Md. Ferdousul Islam Prodhan got married to Mst. Santana Akhter Prodhan on 15 August, 2016



## Congratulations & Best Wishes to the Following Staff and Their Spouses

- Dietician Sanzida Sharmeen had a baby girl Sameeha Aayrah Nina on 28 March 2016.
- CRO Sabrina had a baby girl Nasarrat Islam Manal on 3 April 2016.
- CRO Taslima had a baby boy Nusaid Ibne Shalah on 22 June 2016.
- Obs & Gynae Senior House Officer Dr. Raina Rahman had a baby boy Rayeen Wajeehan Hoque on 25 July 2016.
- Physiotherapist Ummay Kulsum Lizu had a baby boy Ahmed Leian on 30 July 2016.
- Oncology Specialist Dr Sharif Ahmed had a baby girl Yalina Seerat on 16 August 2016.
- Nursing Department's Staff Nurse Sharmin Akter had a baby girl Manha Humaira Jahan on 8 September 2016.
- Senior House Officer Dr Gopal Ghosh of Cardiac Surgery Department had a baby girl Aarya Bharoteshowery Ghosh on 11 September 2016.



## Helping Babies Breathe (HBB)

Dr. Nargis Ara Begum, Consultant, Neonatology and Pediatrics, from United Hospital Limited as a facilitator, attended a Training of Trainers (ToT) on Helping Babies Breathe (HBB) initiative for doctors from Afghanistan. The ToT was held from 24 August to 4 September 2016 at Hotel Lakeshore arranged by the Ministry of Health, World Health Organisation, Laerdal Foundation and Neonatal Forum in Bangladesh. Around 49 doctors from Afghanistan attended this Training.



### Editorial Board

- Dr Mahboob Rahman Khan
- Hanufa Ahmed

### Newsletter Coordinators

- Luna Nasreen Tarafdar
- Syed Ashraf-ul-Masum

### Design

- Jamayet Hossain Russell

### Printed By

- Creation